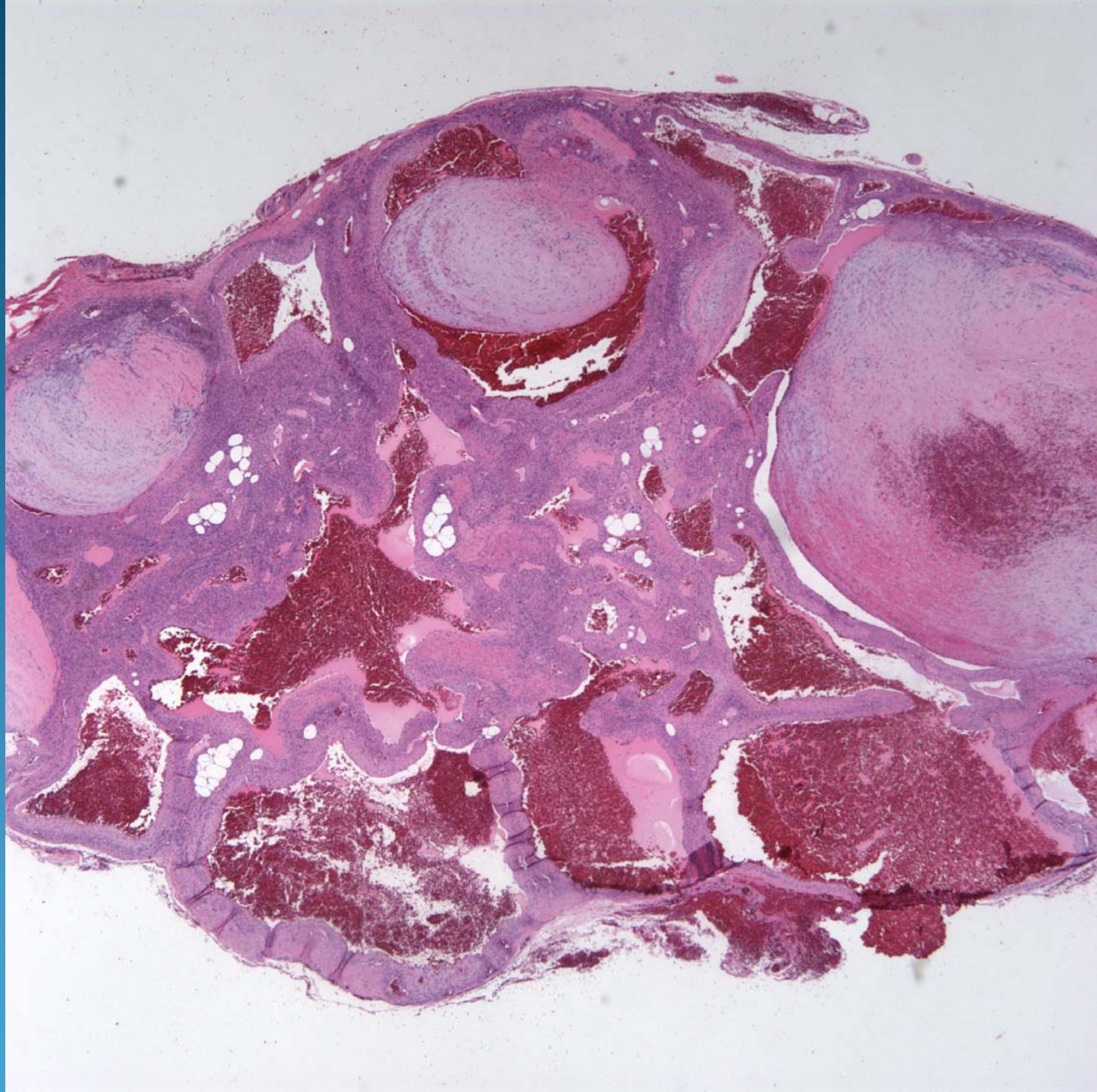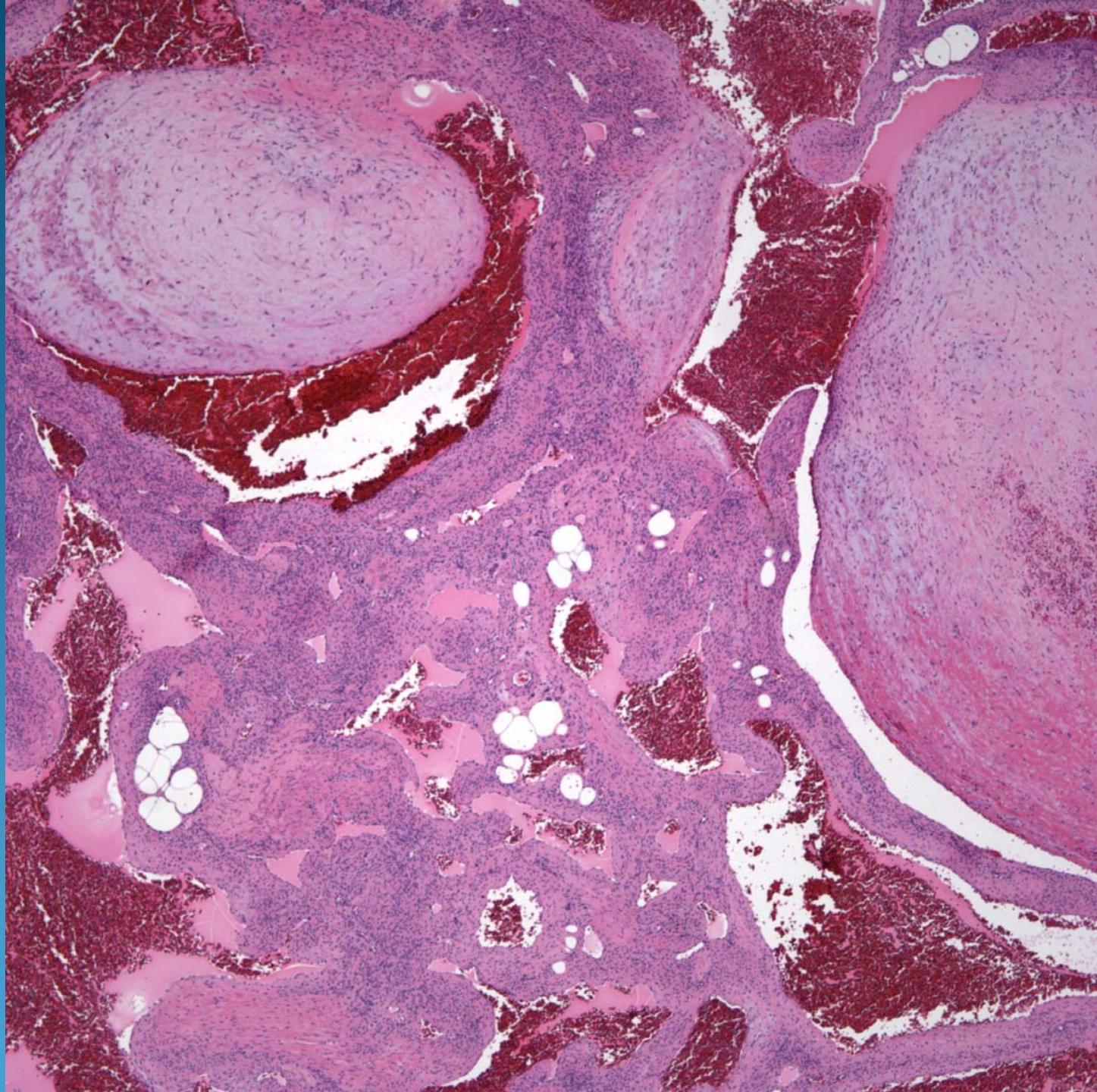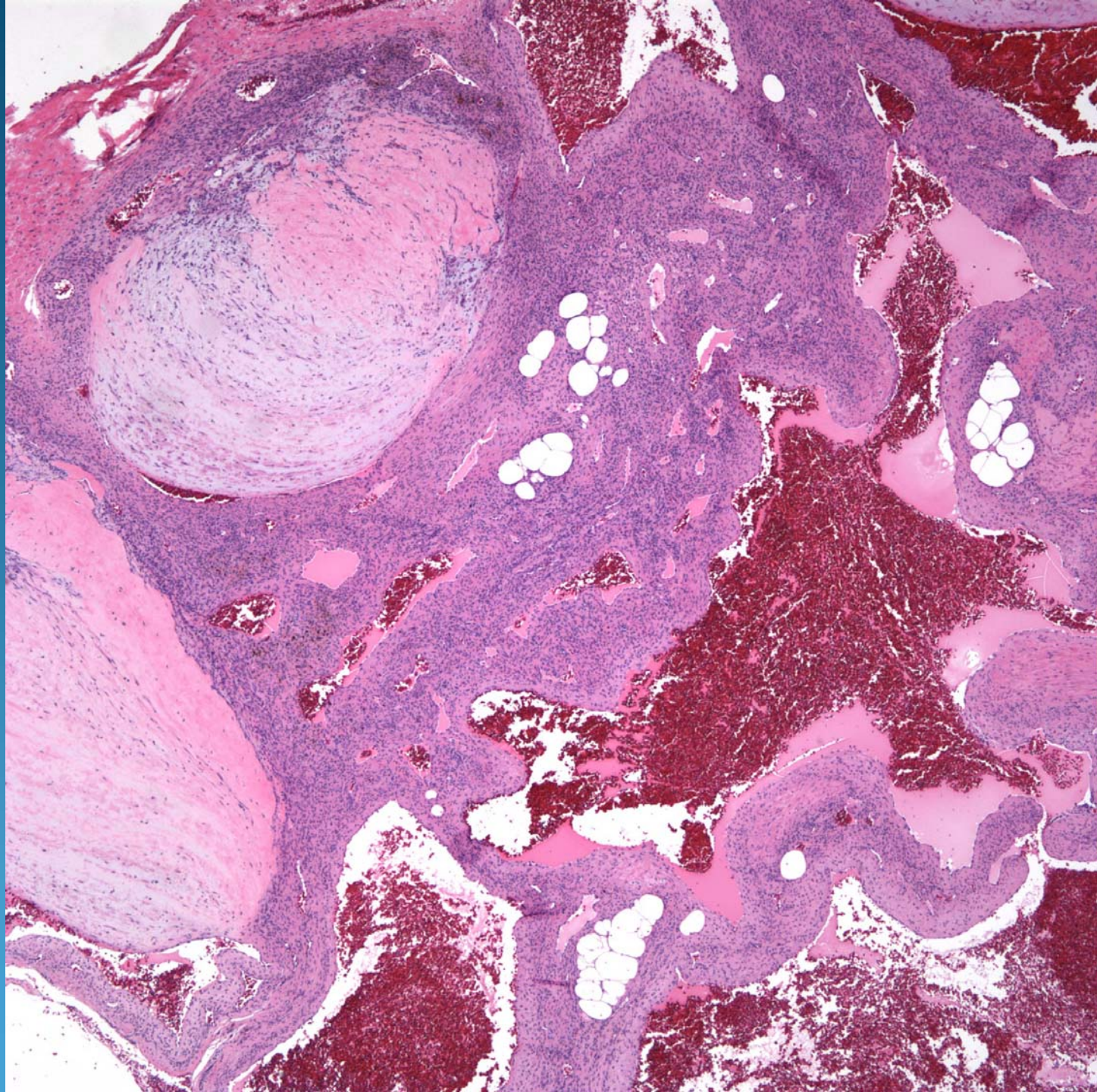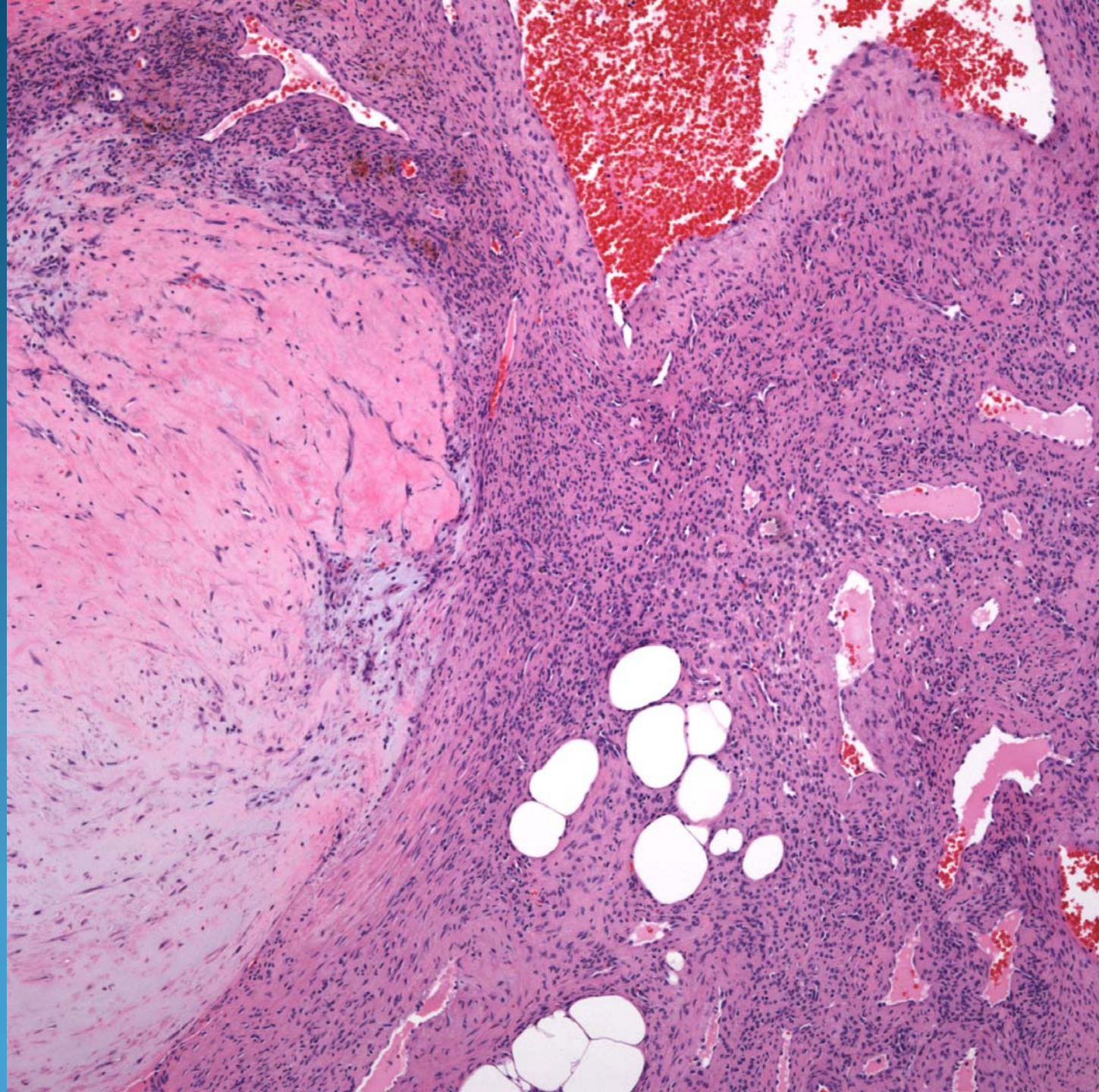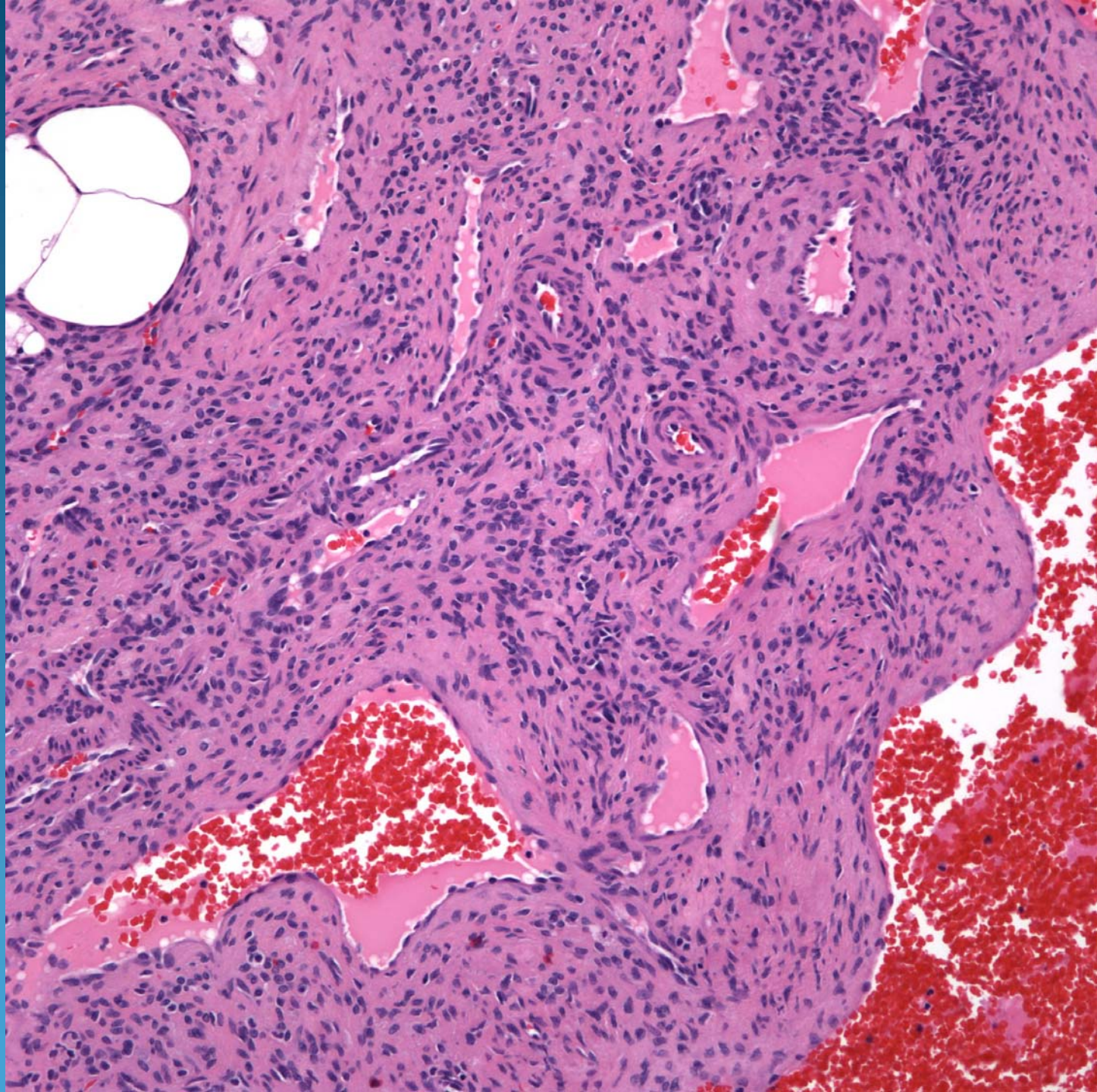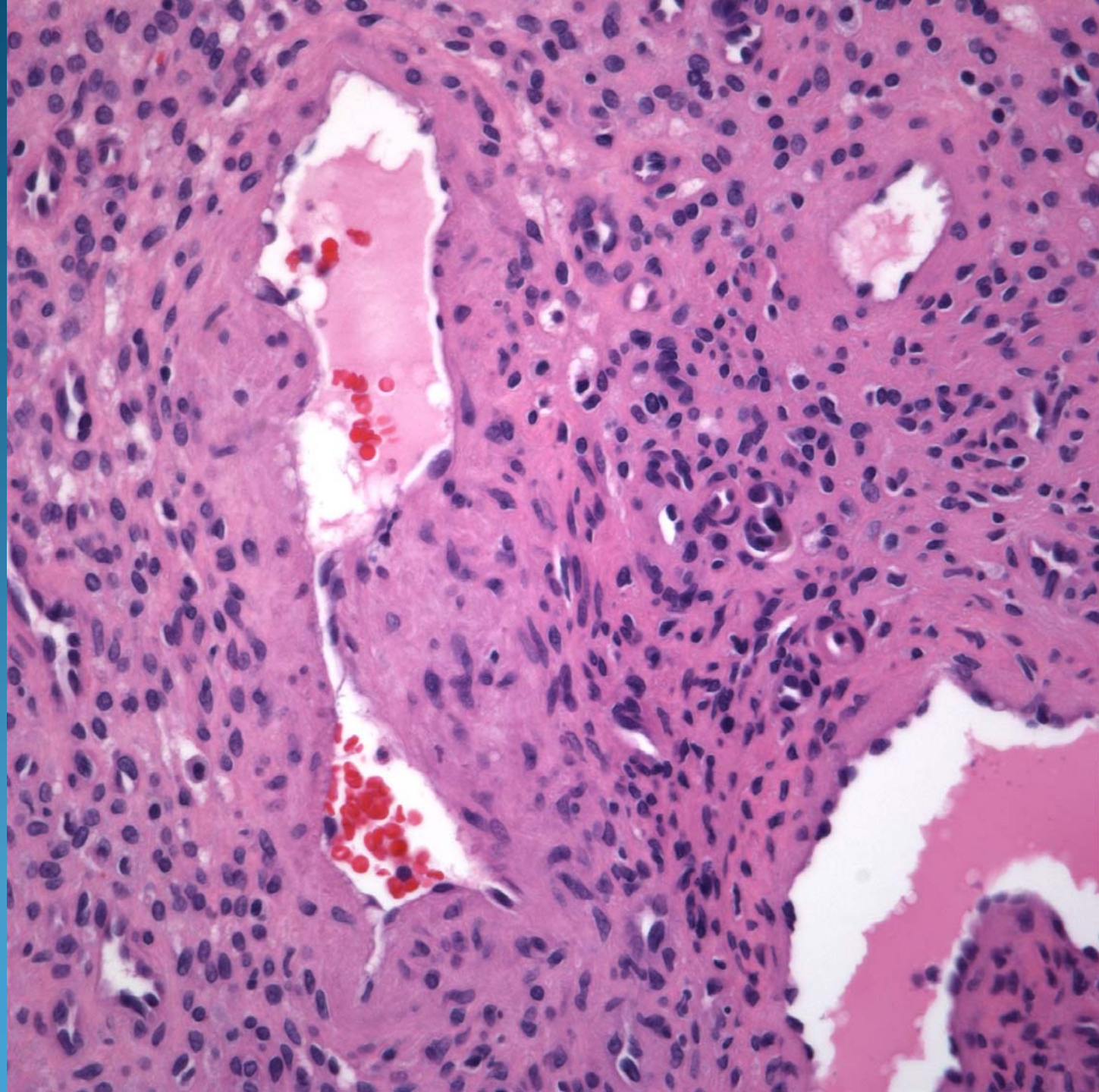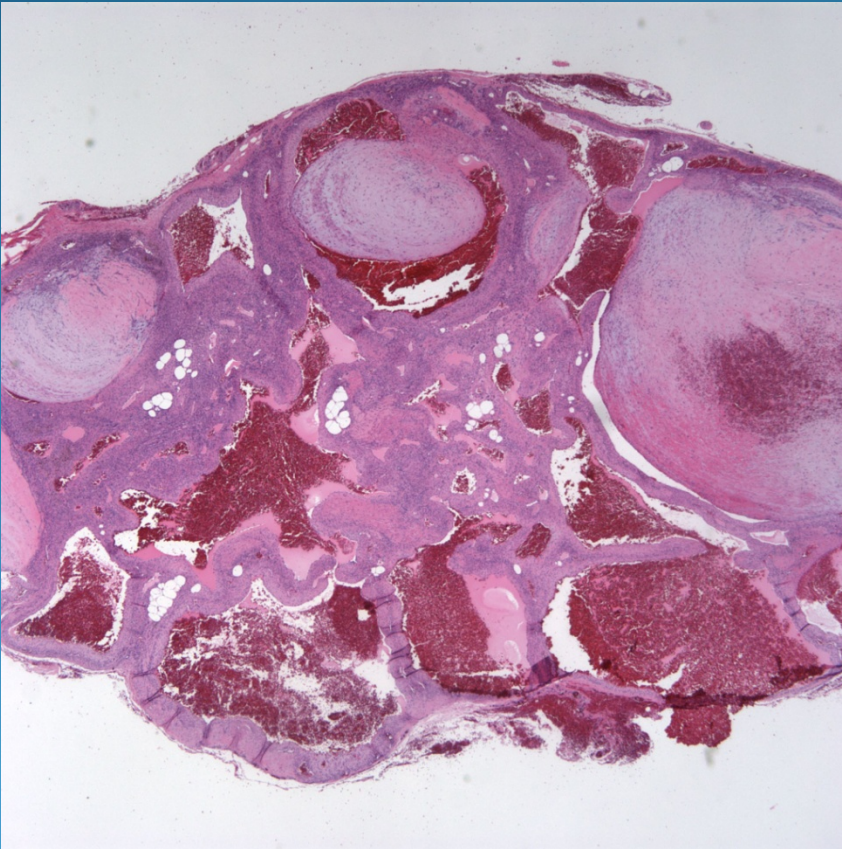


Arterio-Venous Malformation with Organizing Thrombosis

Pearls



- Ectatic vascular spaces composed of thick and thin-walled muscular vessels, frequently sharing a common wall
- Proliferation of capillary-sized vessels between larger vessels
- Secondary thrombosis common